



VCU

Virginia Commonwealth University
VCU Scholars Compass

Theses and Dissertations


Graduate School

2020

The Quantified Elf

Umico Niwa
Virginia Commonwealth University

Follow this and additional works at: <https://scholarscompass.vcu.edu/etd>

 Part of the [Medical Anatomy Commons](#), [Medical Biotechnology Commons](#), and the [Reproductive and Urinary Physiology Commons](#)

© The Author

Downloaded from

<https://scholarscompass.vcu.edu/etd/6338>

This Thesis is brought to you for free and open access by the Graduate School at VCU Scholars Compass. It has been accepted for inclusion in Theses and Dissertations by an authorized administrator of VCU Scholars Compass. For more information, please contact libcompass@vcu.edu.

The Quantified Elf

A thesis submitted in partial fulfillment of the requirements for the degree of Master of Fine Art
in Sculpture + Extended Media at Virginia Commonwealth University.

by Umico Niwa
BFA, Maryland Institute College of Art, Maryland

Thesis reader: Corin Hewitt

Committee Advisors:
Kendall Buster
Gregory Volk
Michael Jones McKean
Corin Hewitt

Virginia Commonwealth University
Richmond, Virginia
2020

TABLE OF CONTENTS:

Abstract	3
I. Vision of a Blue Friend	4
II. A Forest in Miyoshi	7
III. The Valley	10
IV. Pterodactyling Study	13

The Quantified Elf

by Umico Niwa, MFA

Abstract:

The Quantified Elf is an ongoing collection of scientific, medical, archaeological articles and excerpts from my personal journal. It is a way by which I explore the various ways Western notions of personhood subsume human life into constructs of sexuality and gender, overlooking the various other modes of unbridled existence: plant, microbial, fungal, animal, celestial bodies. The speculative medical papers propose novel forms of body modification to combat gender dysphoria.

Vision of a Blue Friend



There I was, suspended at the surface, scuba diving off the coast of Okinawa, my flippers dangling above a school of brightly colored fish. Shortly thereafter, during the boat ride back to shore, a blue butterfly flutters up beside us for a fleeting moment.

“What are you doing all the way out at sea? Do you know where you’re headed?”

By the time we had reached port, I had made a decision to go ahead with getting an orchiectomy. It means the removal of both testicles and by some miracle, I was lying on an operating table three days later.

When it came to having the surgery the anesthesiologist gently placed a mask on my face. He asks me to count down slowly from ten. I begin to do so, ten, nine, eight, it’s all going smoothly but when I get to seven I panic, “what if I want biological children? or to ever feel my dick get hard again? It does feel good, fuck!” My eyes shutter on the count of six but I need more time to process all of this. I’m down to five and my chest is so damn heavy, it feels like I’ve stopped breathing. I tried to scream “please stop” but my mouth won’t move and I think I may have drooled instead. I lose track of what number comes next but with every strength left in my body, I managed to force my eyes open. I hear the anesthesiologist exclaim “oh” before they close once more.

There, suspended in the darkness before me, with those shimmering wings stretched out to me. My blue friend calls out:

“Did your boat safely make it back to shore? Or are you still out there just as lost as me?”

A Forest in Miyoshi



There's this dull ache between my legs as my mother helps to pick out a suitable pad, one with maximal absorption. I'm embarrassed but I savor the bittersweet moment as my father awkwardly hovers beside us. There I was, twenty-six years old, experiencing for all intents and purposes my first, and last, ever period.

The spotting was a result of having undergone a bilateral orchiectomy surgery, a gender-affirming procedure in which both of my testicles were removed.

During the following year, I began to experience these vivid dreams of seed pods germinating, sending their tentacles down into the cool ground as they yearned upwards, towards the blazing sun. These phantom sensations were subtle, distant but mine. I needed to know what became of that part of me, so I began to investigate the medical waste system of the clinic where I had been a patient.

It's been a couple of years since then and I can report back on the whereabouts of my balls: they were transported down to an ecological landfill in the mountains of Miyoshi, on Shikoku island, my home country of Japan, and cremated alongside the testicles and breasts of my transgender siblings. Every so often when I check to see if there are any updated satellite images of the location, I see fresh patches of green and I can confidently say that the future is forest.

Those pixelated aerial shots are reassuring, but after the surgery, there was a period of time where I felt barren. My heart would ache at the sight of babies and I would reassure myself and my mother that I had made the right decision. Since then, my studio is teeming with life, miniature patchwork children: made from foraged plants on my walks and often plated in a variety of metals.

A coconut shell, desiccated cacti, radish, and part of a lychee skin arranges itself into a figure based on a memory I have of my father making business calls. I hold this figure in my arms before gently placing him down among the countless other iterations of him as my mother looks down at me from the window sill. She is wearing a purple lily of the Nile and holding a beautiful baby grape.

The Valley



I climb with my fingertips, these easy inclines, to dance on humble mountain tops. Small soft protrusions signaling hard-won gains. This body, now, at last, ripening at the edges, in preparation to be skewered and consumed. These cheekbones, for example, have slightly risen and I see the glowing smile of my mother. That of apple, round and red. The same ones she used to playfully bite when I was little.

Beneath my shirt, it's warm and dark. Concealed from the public, a couple of mushroom caps have spawned. The darkening of the areola and the budding of a dry fountain. Buried and plowed in a barren land, slightly moist with stagnant waters. I am a valley full of weeds, bursting with life. These are the fruits of my tireless labor and yet who am I to mother?

Pterodactyling Study

A novel surgical approach to alleviating body dysmorphia in young men concerned with their perceived lack of elbow length

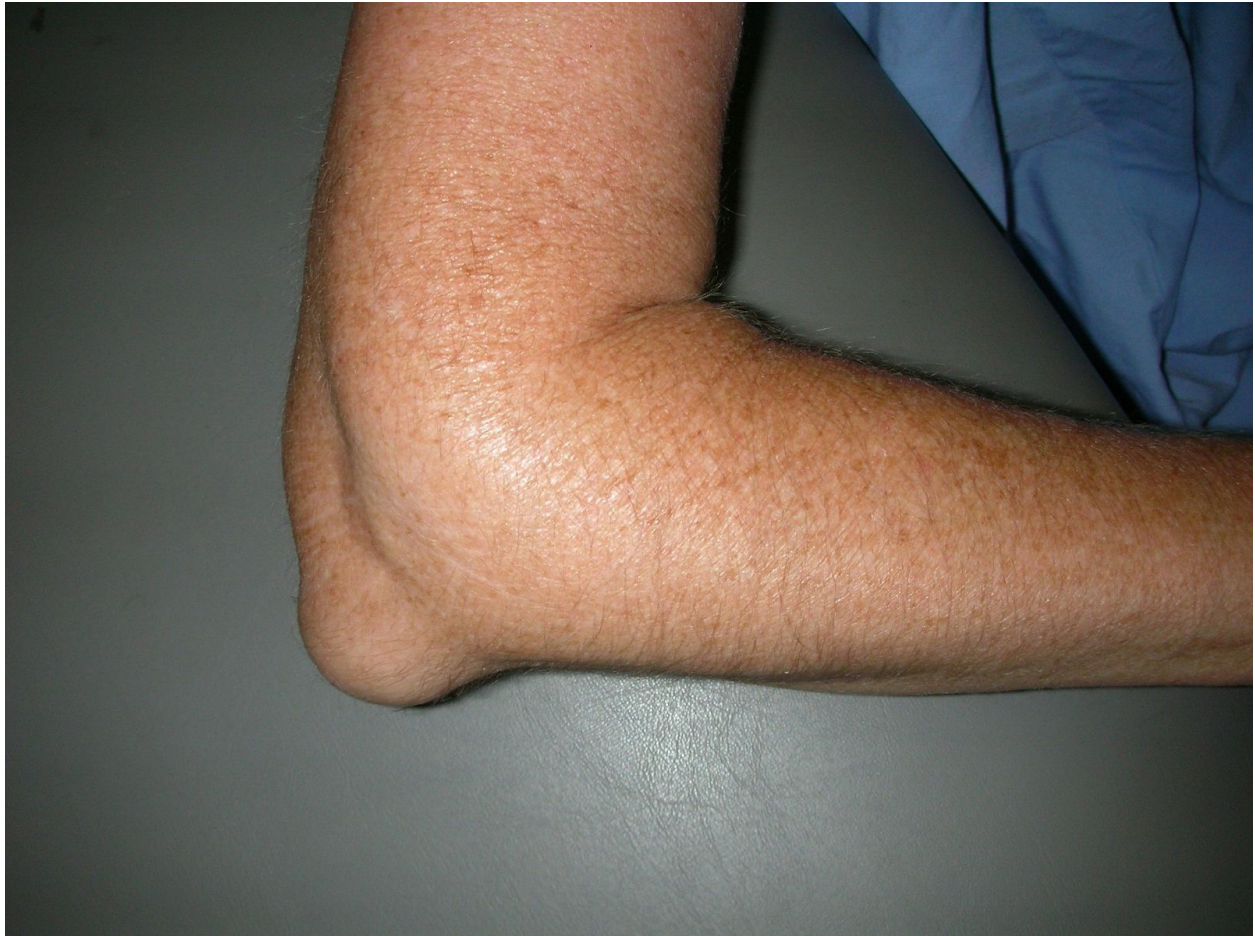Abstract

The purpose of this study is to discuss Medial Epicondyle Elongation Surgery (MEES), the keystone of the treatment of patients with Body Dysmorphic Disorder (BDD) who are specifically concerned with their perceived lack of elbow length. These individuals colloquially known as "Pterosaurs" have been on the rise in recent years. The use of our prediagnostic tool, the Body Image Satisfaction Index (BISI), allows for early recognition of stray nodal points in patients diagnosed with BDD. As a result, many patients can receive successful early treatment so as to avoid the need for a more radical surgical correction at a later stage. Cosmetic surgeons should familiarize themselves with the BISI test in order to empirically assess the severity of Body Dysmorphia (BD) experienced by each patient so as to tailor an Epicondyle Elongation Prosthetic (EEP) of custom length inversely correlating to the Dysmorphic Degree Values (DDV) on the nodal point associated with the elbow to achieve maximal patient satisfaction.

Introduction

Body dysmorphic disorder (BDD), a psychological disorder in which a person becomes obsessed with imaginary defects in their appearance. has been described for over a century and reported in various medical literature, yet it continues to remain underdiagnosed. In the past fifteen years, there has been a spike in young men afflicted with body dysmorphia, localized to the elbow region, these subjects refer to themselves as "Pterosaurs".Figure 1 While clinicians have unanimously noted that this specific, highly localized dysmorphia is emergent and real, the exact cause of this shift in body image expectation for those afflicted remains unclear.

Figure 1

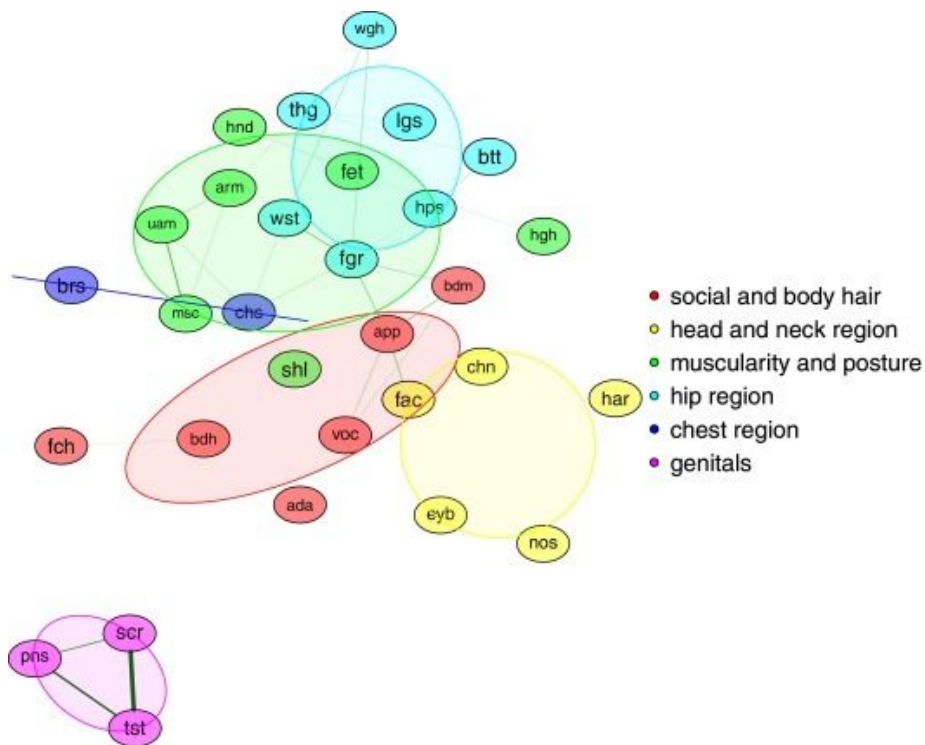


Six weeks postoperative appearance of a patient who had undergone minimal medial epicondyle elongation surgery.

Despite the root cause being unclear, treatment is frequently sought out by those afflicted, particularly by patients whose elbows are less protruded at birth. Medial Epicondyle Elongation Surgery (MEES), popularly known as “Pterodactyling”, has become a routine treatment for men suffering from chronic low self-esteem stemming from their dysmorphia.. The MEES procedure is now widely accepted as routine and therapeutic, but individuals considering MEES and the caregivers who serve as their advisors and medical gatekeepers still have little reliable information concerning the long term outcomes to these surgeries. Though groups such as the Pterosaur Recovery Association (PRA) promulgate their own privately researched Standards of Care for the provision of MEES, caregivers lack empirical information to assess the validity of their recommendations causing confusion and hesitation around the operation.

The primary method of initial diagnosis for undiagnosed transsexuals is the Body Image Satisfaction Index (BISI) test. Because it is readily available online, it serves as a strong and empowering pre-diagnostic tool for preliminary self-assessment. Though BISI tests initially emerged from the field of transgender medical studies, they are now commonly used as an empirical diagnostic tool in various medical fields. Lindgren and Pauly (1975) were the first to quantify the feelings of transgender individuals about their bodies for medical use. They developed the original Body Image Scale for Transsexuals, which was then modified and broadened for use in the general population to measure body satisfaction. BISI theory re-categorizes and projects the human body as a series of mutable nodal points Figure 2

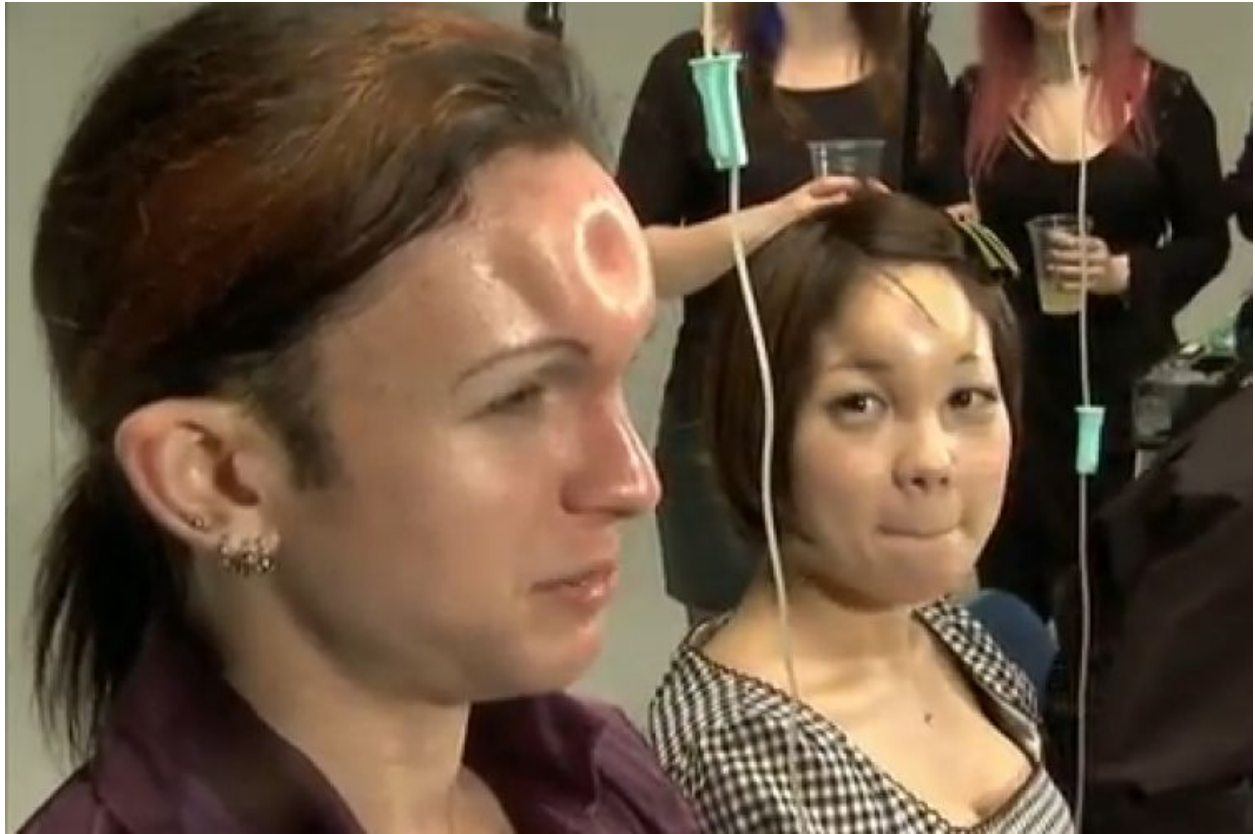Figure 2



Network representation of male-to-female body satisfaction. Legend: $n = 308$; green edges represent positive inter-item correlations of $r > .40$, line width corresponds with the strength of the correlation. Node position represents item centrality. Node colour and overarching ovals mark subscales. ada = Adam's apple, app = appearance, arm = arms, bdh = body hair, bdm = body movement, brs = breast, btt = bottom, chn = chin, chs = chest size, eyb = eyebrows, fac = face, fch = facial hair, fet = feet, fgr = figure, har = hair, hgh = height, hnd = hands, hps = hips, lgs = legs, msc = muscles, nos = nose, pns = penis, scr = scrotum, shl = shoulders, thg = thighs, tst = testicles, uam = upper arm muscles, voc = voice, wgh = weight, and wst = waist.

Using the BISI method, surgeons are able to assess and prescribe customized surgical options and prosthesis to bypass the “one-size-fits-all” approach that was typically seen utilized in body dysmorphia (BD) corrective surgeries of the past.

Figure 3



Photograph of successful bagel-heading, courtesy of Medical Daily.

Figure 4

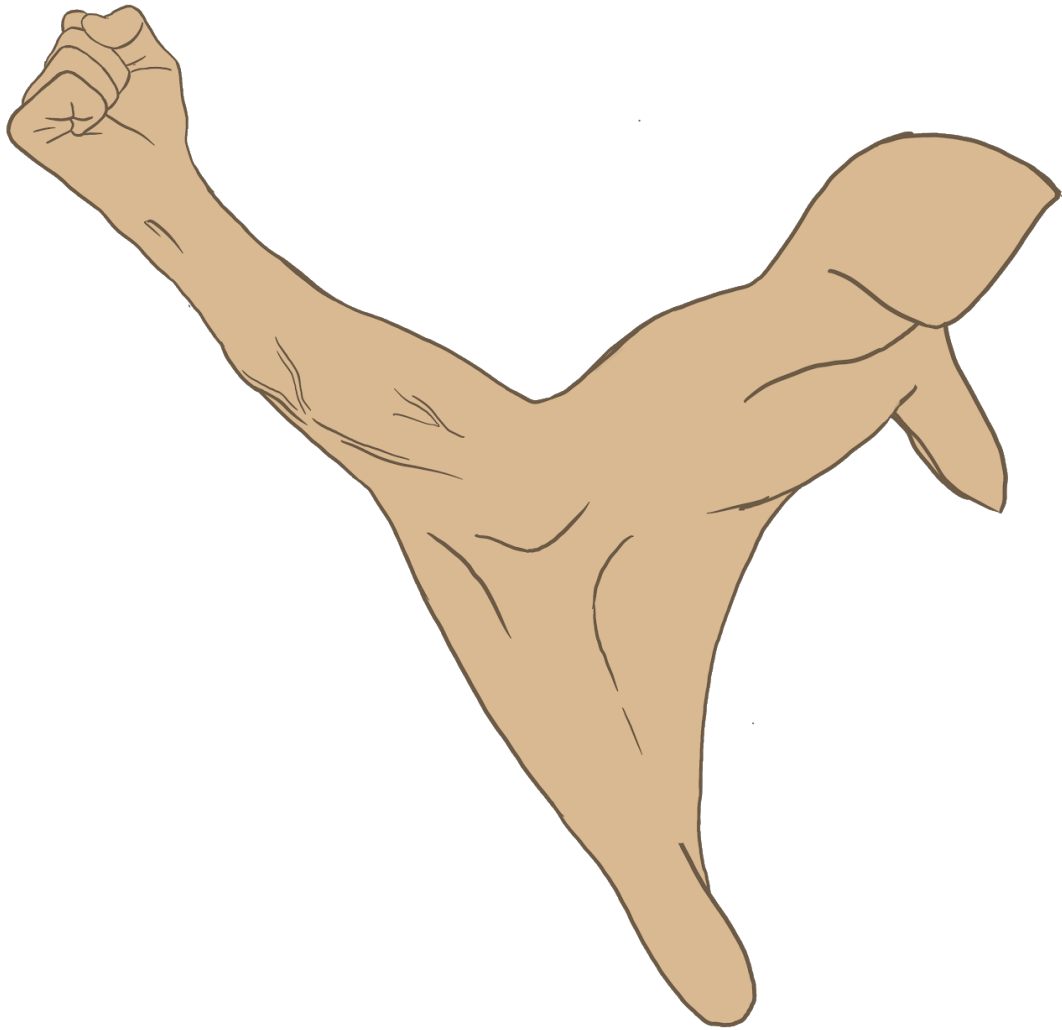



Illustration of a postoperative pterosaur arm.

Methods & Materials

The study examined by this article was performed between 2007 and 2018 by Carleson and Jaime. A total pool of 305 men diagnosed with body dysmorphic disorder (BDD) based low self-esteem who desire for the pterodactyling surgery were given BISI tests in early 2007. 72 of the polled men went on to, over the next 3 years, receive the pterodactyling surgery. The group of 72 pterosaurs were then polled against 223 pre-operative men over the course of 9 years. A specialized BISI test utilizing the nodal point based body satisfactory tests was taken every six months by both groups. Figure 5

Figure 5



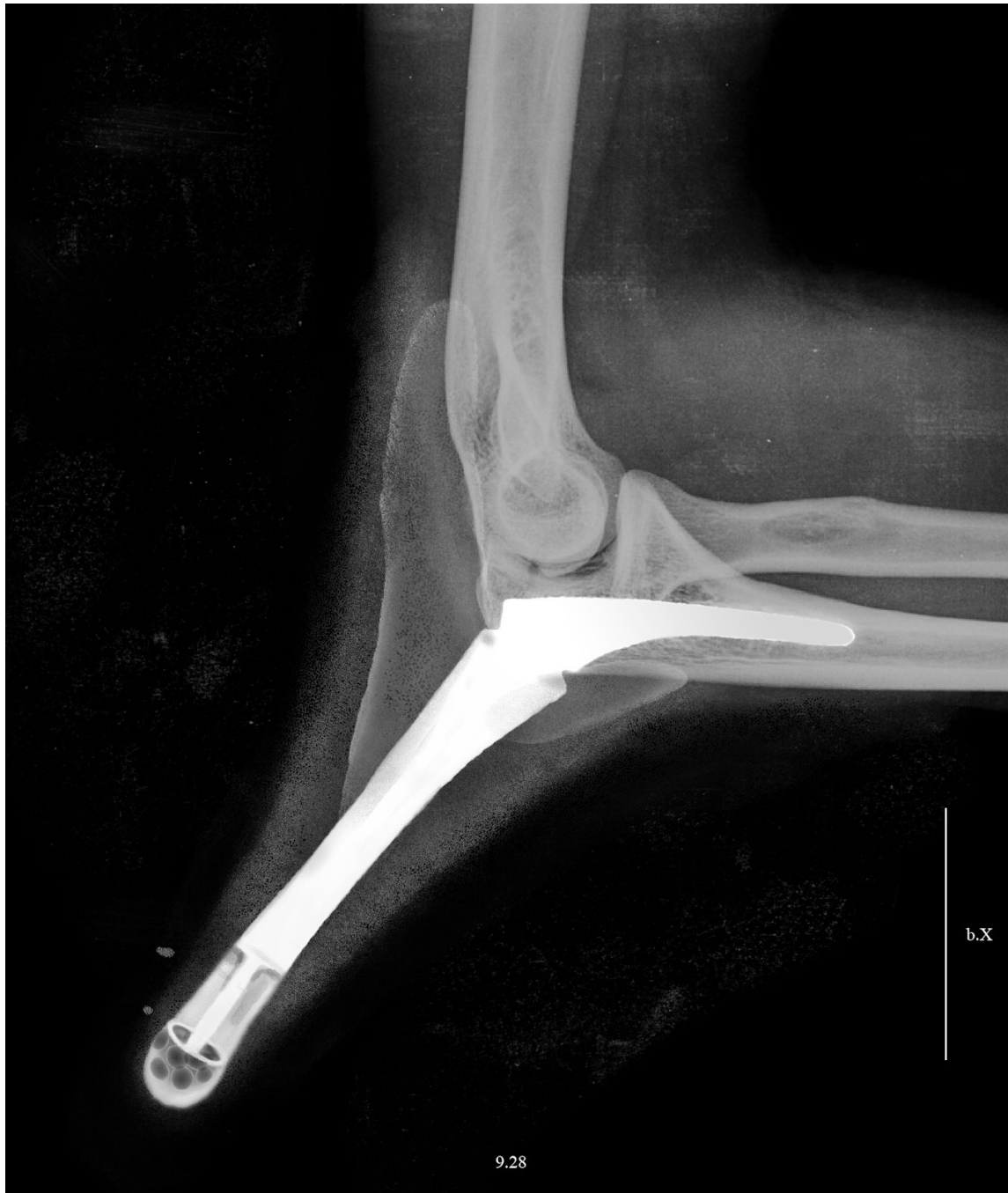Simplified nodal network diagram of person exhibiting need for pterodactyling.

It measured body satisfaction of each participant every six months and compared the updated scores against their own pre-surgical score, their peers' scores, and the scores of the men who never received the surgery.

The surgery itself is a delicate and lengthy form of modified arthroscopy. Because of the relatively large size of the metal pterodactyl implant, open surgery is required, rendering modern methods of arthroscopy impossible. The specific length and shape of the implant is honed by the results of repeated BISI nodal testing in the months prior.

A long incision is made along the outside of the elbow revealing the anconeus muscle and olecranon of the ulna. The surrounding muscular structures and the anterior olecranon crest is drilled hollow. The porous-coated ulnar implant is inserted and bolted into place along the length of the ulna. The olecranon fossa of the humerus is shaved down to accommodate the new prosthetic. Figure 6

Figure 6



X-ray of a successful medial epicondyle elongation surgery using an implant made of the material, BioloX® Delta, an alumina matrix composite consisting of approximately 75% alumina and roughly 25% yttria-stabilized tetragonal polycrystalline zirconia (Y-TZP). There is very little swelling due to the use of human tissue-engineered vascular grafts (TEVGs) at the sites of incision.

The muscles of the area are carefully placed over the prosthetic insert and, depending on the size of the new pterodactyl wing, either a stepped gauging system is used to extend the length of the new appendage or, in extreme cases, skin grafts from the inner thigh of the patient are used in the suturing process and a mesh of ligaments is placed underneath. The surgeon should specialize in MEES in order to achieve results with minimal scarring, improving the image of the patient.

Results & Discussion

Of the 72 pterosaurs in the study, all 72 went on to report a higher level of satisfaction with not only their bodies, but their lives afterwards. In fact, the postoperative BISI tests taken show increased body satisfaction across the board.

The men unable to receive the surgery, as the number of visible pterosaur men increase in society, report sensations of a “phantom [pterodactyl] wing” jutting from their elbow. The examined study by Carleson and Jaime, while pushing forward the legitimacy and recognition of pterosaurs, was disappointingly narrow in its scope. The study was limited to a one-dimensional measurement of body image, namely body satisfaction in exclusivity.

There is currently a need for future studies that take into account a variety of body satisfaction behaviors, including desire for further modification beyond pterodactyling, lifestyle factors, medical complications, length of time of social reintegration, and long term mental health follow ups among other criteria to test the validity and reliability of body dissatisfaction and body image satisfaction measures. Future studies also should take into account participants' beliefs about the effectiveness and the potential risks of certain interventions. The benefits of surgery over supplying preoperative pterosaurs with a supplemental strap-on prosthetic is another place the literature is lacking.

Conclusion

While the pterodactyling procedure produces innumerable definite benefits in the raising of young men's immediate and prolonged self-esteem and alleviation of dysphoria, extra steps need to be taken to ensure the sustained long term mental and physical health of those undergoing the procedure. If the surgery is successful and the implant is placed, it has a lifespan of 15 to 20 years. When it is removed, the piece is replaced with the latest appropriate prosthesis.

The goal in the next 10 years is to improve the current implant offerings so as to make surgical maintenance as infrequent as possible.

BDD and self-esteem issues being targeted specifically through the BISI nodal diagnosis system, societal reintegration period for pterosaurs is astoundingly fast with positive benefits across the board, such as increased relationship longevity. A 2005 study found that roughly 35% of the 333 men who had undergone the surgery were in committed relationships, and by the end of their lives, 86% of these pairs were happily married. Speaking about the statistics, Bob Houde, president of the Pterosaur Recovery Association (PRA), said, "It is great to see that pterosaurs are a welcome member of the society. That is an accomplishment, truly. We are able to communicate with those close to us that surgery is not a wrong action, but an adaptive process, a natural, necessary, healthy process to correct those body image problems.

So often in these cases, the intention to become a more masculine, confident man goes to greater effect if the subject is proactively addressing an oft overlooked area of his body image, with regards to pterosaurs, small elbows.

The rapid medical implementation and social acceptance of the pterodactyling procedure offers a radical path forward in nodal cascation (NC) as a means of repairing self-esteem, heightening physical attributes and traits, pruning excess nodal points, and streamlining the diagnostic process, not only for young men diagnosed with a severe case of BDD, but the population at large going forward.